

HARVARD UNIVERSITY.



LIBRARY

OF THE

MUSEUM OF COMPARATIVE ZOÖLOGY.

29070.

GIFT OF

ALEXANDER AGASSIZ.

June 15, 1870.
Entered April 5, 1907.

JUN 15 1900

With the compliments of
Franklin Dexter

ADDITIONAL OBSERVATIONS

ON THE

MORPHOLOGY OF THE DIGESTIVE TRACT OF THE CAT

LIBRARY
MUS. COMP. ZOOLOGY
CAMBRIDGE, MASS.

FRANKLIN DEXTER, M.D.
(Assistant Professor of Anatomy in the Harvard Medical School)

Reprinted from
THE JOURNAL OF THE BOSTON SOCIETY OF MEDICAL SCIENCES
VOLUME IV., pp. 205–212, April, 1900

BOSTON
MASSACHUSETTS
U.S.A.

LIBRARY
MUS.COMP.ZOOLOGY
CAMBRIDGE, MASS.

JUN 15 1900

ADDITIONAL OBSERVATIONS

ON THE

MORPHOLOGY OF THE DIGESTIVE TRACT OF THE CAT.

FRANKLIN DEXTER, M.D.

(*Assistant Professor of Anatomy in the Harvard Medical School.*)

In a paper published about a year ago, entitled [1] "On the Morphology of the Digestive Tract of the Cat," I showed that there was a period in its development when certain portions of the intestine were contained in the cavity of the umbilical cord, and that this cavity was continuous with the abdominal cœlom. The peculiar position of these portions of the digestive tract was chiefly attributed to the enormous size of the liver. This organ practically fills the abdominal cavity, and so forces the intestines to develop in the cavity of the umbilical cord. It was also noted that the liver develops in the direction of least resistance.

After a time those divisions of the intestine which are developed in the cavity of the umbilical cord leave it and enter the abdominal cœlom. Their entrance takes place in a regular and definite order.

The stomach and duodenum are always contained in the abdominal cœlom, and never leave it. The first centimetre or so of the jejunum would necessarily also be situated here, but the greater part of it, as well as all of the ileum, the cæcum, and a short stretch of the colon, are contained in the cœlom of the cord. This short stretch of colon is continuous with its caudal portion, which is contained in the abdominal cœlom. The definite order of entrance is as follows: A simultaneous entrance of the two extremities of the intestine,

[1] His' Archiv., 1899.

the jejunum, and colon. This process continues until the cæcum lies in close apposition to the stomach. (Fig. 3.) That portion of the colon which was formerly contained in the cavity of the cord now lies within the abdominal cœlom, together with (approximately) a corresponding length of the jejunum.

The entrance of the caudal end of the digestive tract now ceases, but the jejunum continues to enter the abdominal cœlom, until finally all that remains in the cavity of the cord is a loop of ileum situated a few centimetres from the cæcum, and this is the last portion of the intestine to enter the abdominal cavity proper.

In my former article no explanation whatever could be offered regarding the mode of entrance of the intestines, nor any reason given for their definite order of entrance. These two subjects form the chief topics of the following observations.

All the drawings were made with the aid of a camera lucida from sections of cat embryos, and Figs. 1, 2, 3, 4, and 5 were drawn on the same scale.

Fig. 1 is a sagittal section of an embryo $15\frac{1}{5}$ millimetres. An examination of such a section demonstrates perfectly how completely, at this stage, the entire abdominal cavity is filled by the liver, stomach, vessels, and colon, while most of the small intestines and cæcum are seen in the cavity of the umbilical cord. It shows also the great size of this cavity as compared with the abdominal cœlom.

Fig. 2 represents a sagittal section of an embryo 24 millimetres. The stage of development is more advanced than in the last figure. The colon, the cæcum, and a few coils of jejunum may be said to have entered the abdominal cœlom, but the cæcum has not as yet reached its characteristic position (and one which it will occupy for some time to come) in close proximity to the stomach.

Fig. 3 is a sagittal section of an embryo $34\frac{3}{5}$ millimetres. It represents a still more advanced stage of intestinal development than either of the previous sections. The cæcal extremity of the colon and cæcum lie close to the stomach, the

jejunum and probably a portion of the ileum have entered the abdominal cœlom, but there still remain many coils of ileum in the cavity of the umbilical cord. This section shows well what is not at all uncommon, namely, the presence of a large amount of liver in this cavity.

Fig. 4 is a sagittal section of an embryo 38 millimetres, and is a much more advanced stage of intestinal development. The position of the cæcum and colon is not materially altered, but all of the small intestines are here intra-abdominal, with the exception of a coil of ileum situated a few centimetres from the cæcum.

In Fig. 5, a section of an embryo $38\frac{3}{5}$ millimetres, all the intestines have left the cavity of the umbilical cord, and there is now nothing contained therein except the vitelline artery and vein.

To recapitulate — these sections represent five progressive stages of intestinal development: Fig. 1 shows the normal umbilical hernia to be at its height, for all those divisions of the intestine (that are ever found there) are in the cavity of the cord.

In Fig. 2 the two extremities of the intestine (the jejunum and colon) are entering the abdominal cœlom.

In Fig. 3 this entrance has not only been completed, but the entire jejunum is now contained in the abdominal cœlom and only a portion of the ileum remains in the cœlom of the cord.

The entrance of the ileum is almost completed in Fig. 4, as only a short loop of intestine now remains outside of the abdominal cœlom.

Fig. 5 shows the umbilical cœlom to be void of intestines, and to contain only the vitelline vessels.

It is evident that before the intestines can enter the abdominal cœlom, space must be provided for their accommodation. This is accomplished in various ways, which I will mention in their order of importance.

Naturally the abdominal cavity of an embryo of $38\frac{3}{5}$ millimetres (Fig. 5) will present a greater capacity than that of an embryo of only $15\frac{1}{5}$ millimetres (Fig. 1), but at the

same time, on comparing Figs. 1, 2, 3, 4, and 5 it is clearly demonstrated how much more developed the lower part of the abdominal and pelvic cavities is in the older than in the younger stages. This pelvic growth is perhaps the single most potent factor in the provision of room for the intestines.

In a recent paper [1] Mall finds this same state of affairs to exist in the human embryo.

The diaphragm is distinctly more concave in the older than in the younger embryos. As development proceeds this concavity of the diaphragm increases the capacity of the abdominal cavity, which is easily understood on comparing the Figs. 1 to 5.

We have already seen that the liver develops in the direction of least resistance, and so it is not surprising that it should change its shape in order to conform to the concavity of the diaphragm, and thus to develop cephalad, so leaving more space caudad for the intestines.

The vitelline vessels (omphalo-mesaraic, superior mesenteric) are certainly much larger, in proportion to the size of the embryo, in the younger than in the older stages. I am inclined to believe that they are actually very little larger in an embryo of $38\frac{3}{5}$ millimetres than in one of 15 millimetres, but my sections have not allowed me to surely determine this point. Be that as it may, these vessels in the young embryo occupy a very appreciable amount of space, and are an important factor in the consideration of the contents of the abdominal cavity. They have one curious characteristic, and that is that in embryos of from 8 to 15 millimetres the diameter of both the artery and the vein gradually increases as they approach the yolk sack.

This interesting artery will probably be the subject of a future investigation, which I hope soon to complete.

The Wolffian bodies are proportionately larger in the younger than in the older stages, but on the other hand it must be remembered that a portion of the space thus gained in the older embryos is partially utilized in the development of the true kidneys.

[1] Anat. Anzeiger, Bd. XVI., 1899.

In these various ways room for the intestines is obtained in the abdominal cœlom.

The cavity of the umbilical cord is obviously very much larger, in proportion to the abdominal cavity, in the younger than in the older embryos (Figs. 1, 2, 3, 4, and 5). Its cavity increases in size up to the time that the intestines leave it, which would correspond to an embryo of from 20 to 30 millimetres in length. It then steadily atrophies until its cavity is practically obliterated. The obliteration of this cavity is due to a thickening (*i.e.*, to an increase of the mesenchymal tissue) of the somatopleure, which forms its walls, as well as to a distinct contraction of the walls themselves (Figs. 1, 2, 3, 4, and 5).

The intestines enter the cœlom proper by growth.

Space for their occupancy has been provided for them in the different ways already enumerated, and their natural growth or development takes them there.

At first this seems to be a most disappointing, a most unsatisfactory conclusion. One might like to have them pulled in by their mesentery or pushed in by the union of the somatopleure, but I can find no evidence either in my sections or dissections of anything of this kind taking place.

There is no reason why the mesentery should have the power of contraction, and surely if the closure of the walls of the cord exerted any pressure upon them one would expect to find the walls furrowed and grooved, after the manner of the liver, which seems to keep them in the cavity of the cord (Fig. 1).

There are several phenomena of this same kind in the human body — examples of migration by growth. I will mention only one — the descent of the testicle. No one to-day believes that the mesorchium drags the testicle to the scrotum. It may possibly be its guide, but it is not believed to have the power of placing it there. The testicle reaches its destination by growth; and by this same process, when the abdominal cavity is ready to receive them, the intestines enter it, possibly also guided by their mesentery.

The definite order of entrance of the intestines is dependent upon the vitelline vessels.

These vessels may be easily identified before the union of the somatopleure to form the ventral wall of the embryo, and at that period when the intestine forms a simple loop or bend. This stage corresponds to an embryo of from six to ten millimetres in length.

Fig. 6 represents a frontal section of an 8-millimetre embryo. The embryo was somewhat twisted, which made the section a very fortunate one for my purpose, and the somatopleures have not as yet united. The loop of intestine is easily recognized, with the longitudinally cut vitelline artery in its mesentery. The artery crosses the intestine where the loop is formed, and then passes on to the yolk sack, about which it divides, and to which it is finally distributed. In a more advanced stage of development, after the concrescence of the somatopleure, the artery and vein are found in its mesoderm previous to their division around the yolk sack. This is well shown in Fig. 7, which represents a transverse section of an embryo $15\frac{3}{5}$ millimetres. In the cavity of the umbilical cord a portion of the vitelline vein is seen, as well as the artery and vein contained in the tissue of the somatopleure.

As we have already said, the first step of the entrance of the intestines into the abdominal cœlom is a simultaneous entrance of its two extremities, the cæcal and jejunal. This process continues until the progress of the ileum is arrested by the vitelline artery, which crosses and fixes it, by means of its attachment to the mesentery of the ileum on the one hand, and to the tissue of the somatopleure and yolk sack on the other. In other words, a portion of the ileum, situated a few centimetres from the cæcum, by means of these vessels becomes anchored in the cavity of the umbilical cord. Its further entrance is rendered impossible.

Growth continues, and the jejunum, unhindered, enters the cœlom proper, and then the ileum enters, until only a loop of the ileum is left in the cavity of the cord, which is crossed and fixed there by the vitelline vessels.

These vessels now begin to elongate, and as they lengthen, this coil of ileum is gradually allowed to enter the cœlom,

until finally the cavity of the umbilical cord contains only the elongated vitelline vessels (Fig. 5).

Macroscopically these vessels present the appearance of fine threads. They can be identified in an embryo of fifteen millimetres, or more easily in an older one, and curiously enough I find that the artery is pervious at birth and can be injected with Teischmann's mass.

It is my belief that the fixation of the ileum is more directly due to the artery than to the vein. In all my sections the artery lies within the mesentery of the intestine, whereas the vein does not seem to be actually connected with it, but is placed close to it. A glance at Fig. 8 will make this quite clear. It is a frontal section through the cavity of the umbilical cord of an embryo of $13\frac{1}{5}$ millimetres. The vitelline artery may be recognized in the tissue of the mesentery which is connecting together two bits of intestine. The vein lies cephalad from it, quite isolated and alone. For this reason it seems probable that the artery is a more potent factor in the fixation of the ileum than the vein.

Mall finds that in the human embryo the cæcum is the last portion of the intestine to enter the abdominal cavity.

It seems to me more than probable that the order of entrance in the human subject will also be found to depend upon the vitelline artery, as I find that in the few human embryos at my disposal the relation of the vessels to the intestine, as well as a persistence of them after the intestines are intra-abdominal, resembles very closely their relation in the cat.

The abdominal cavities of ninety-three cats were examined for Meckel's diverticulum, but in vain. This can probably be accounted for by the very early separation of the yolk sack from the intestine. Its absence was a disappointment to me, for if it could have been found in a sufficient number of cases to establish its normal position, it would have been interesting to compare it with the position of the human diverticulum. Since the cæcum enters the abdomen first in the cat and last in the human subject, one would expect to find the diverticulum farther from the cæcum in the former than

in the latter. It is most natural that this difference in the order of entrance of the intestines should exist, for in the human subject the transverse colon lies ventrad to the small intestines, whereas in the cat it is placed dorsad to them.

I feel under great obligations to Prof. C. S. Minot for his kindness in verifying this piece of work, as well as for the assistance he has afforded me in its production.

ABBREVIATIONS.

Am.	Amnion.	J.	Jejunum.
Al.	Allantois.	L.	Liver.
Al. art.	Allantoic artery.	L. u. v.	Left umbilical vein.
Ao.	Aorta.	Œ.	Œsophagus.
C.	Colon.	S.	Stomach.
Cæ.	Cæcum.	U. v.	Umbilical vein.
C. u. c.	Cavity of the umbilical cord.	V. art.	Vitelline artery.
C. v.	Cardinal vein.	V. v.	Vitelline vein.
G. o.	Great omentum.	W. b.	Wolffian body.
I.	Intestine.	Yk.	Cavity of yolk sack.

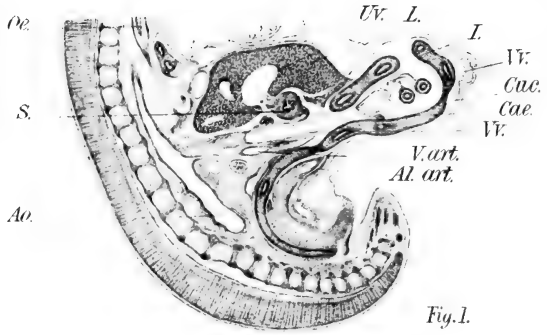

Fig. 1.

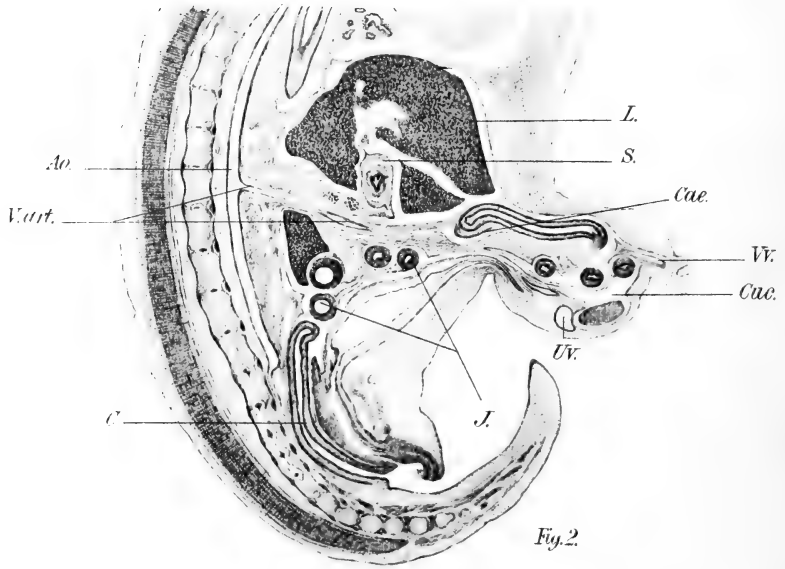

Fig. 2.

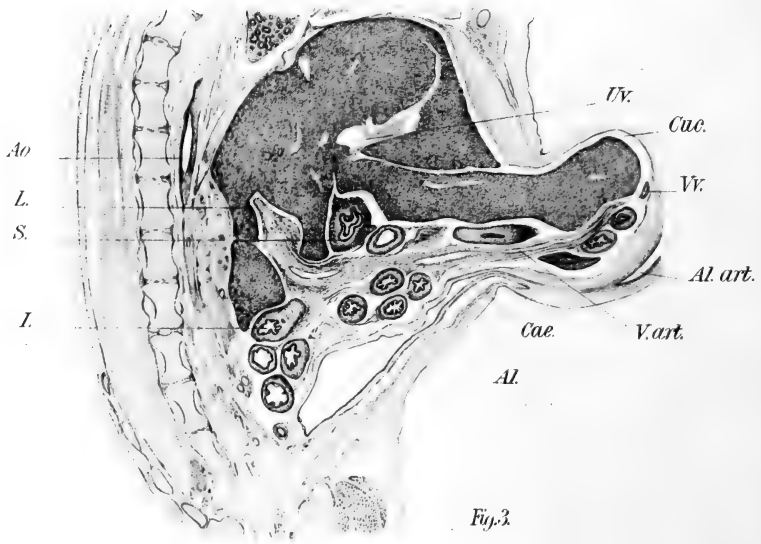

Fig. 3.

Heliotype Co, Boston.

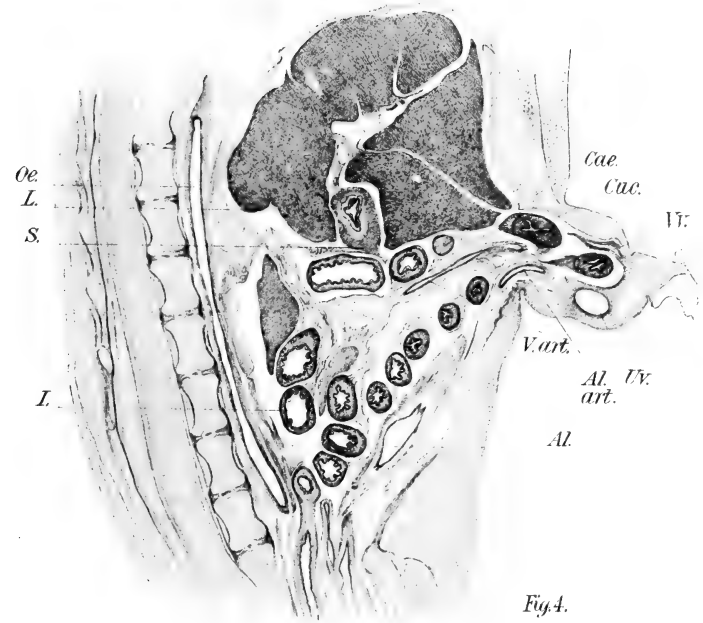

Fig. 4.

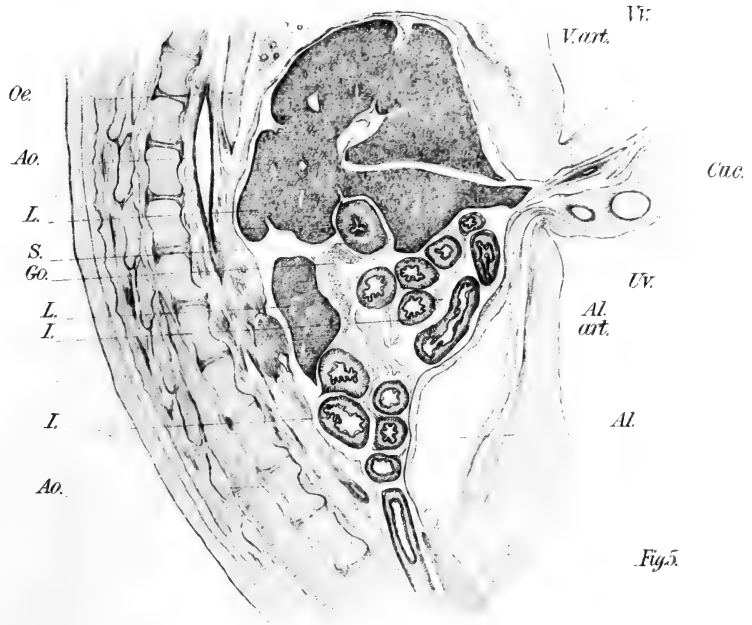

Fig. 5.

Heliotype Co. Boston.

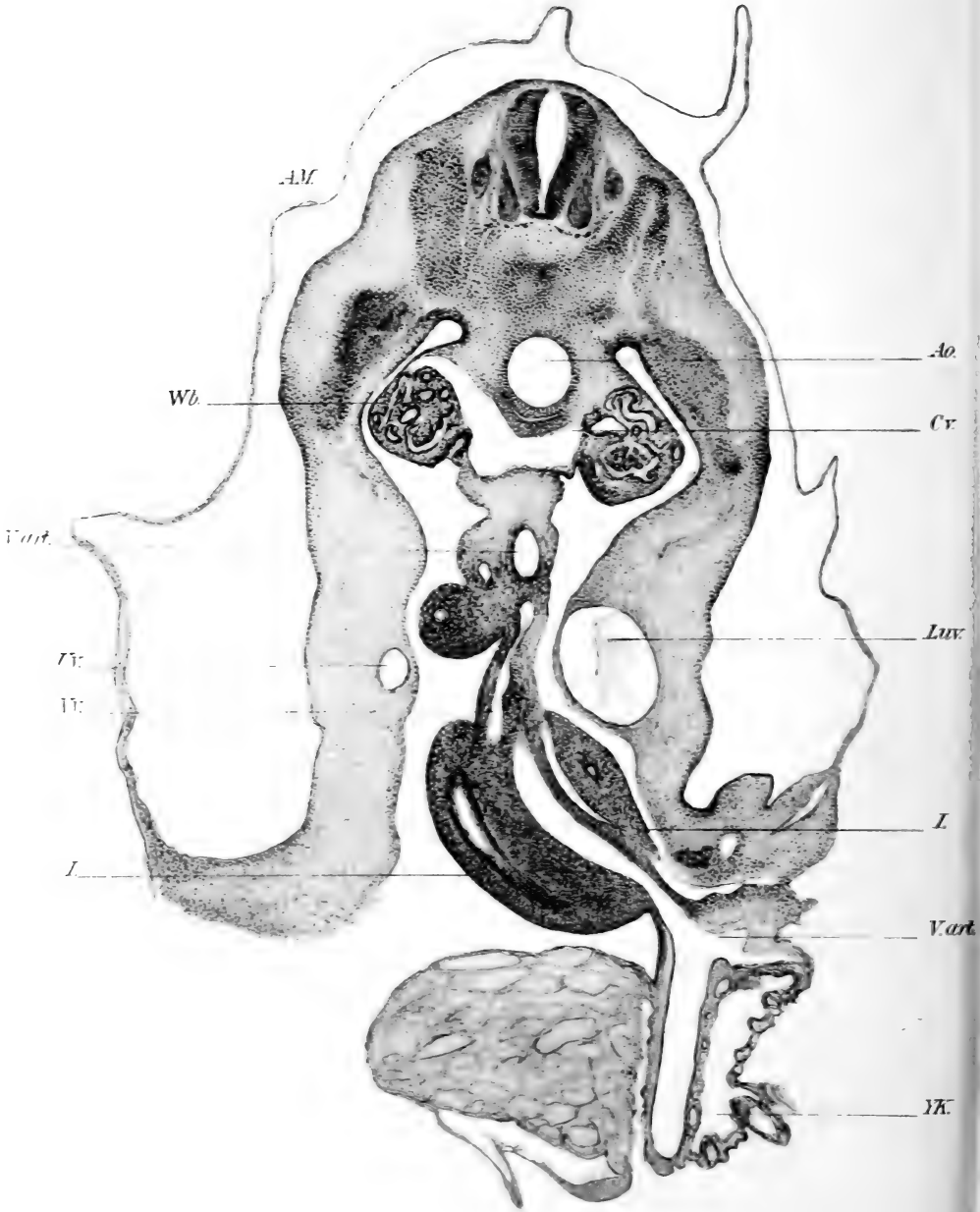

Fig.6.

Heliotype Co. Boston.

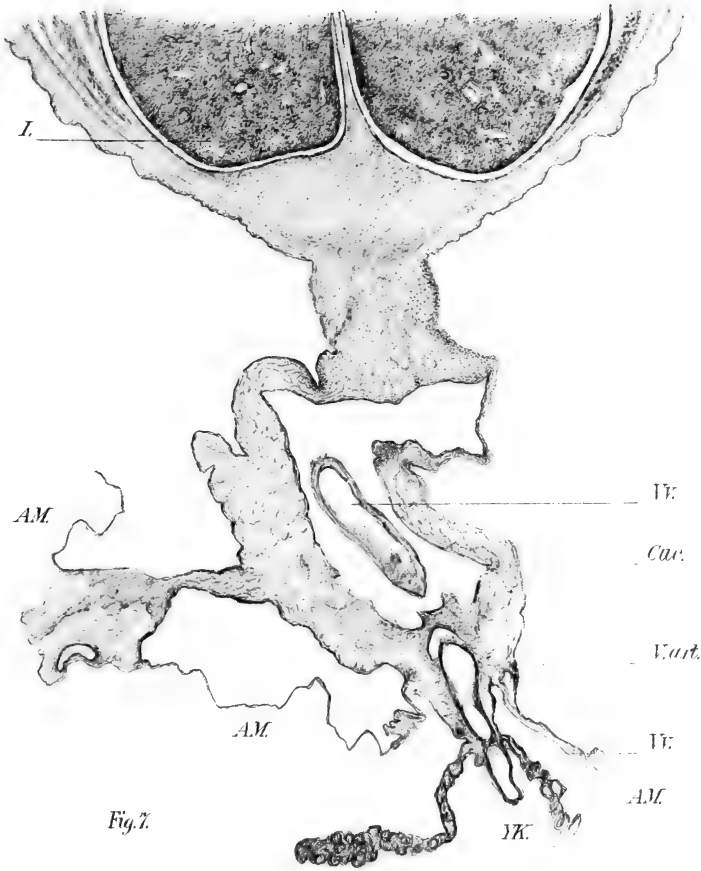

Fig. 7.

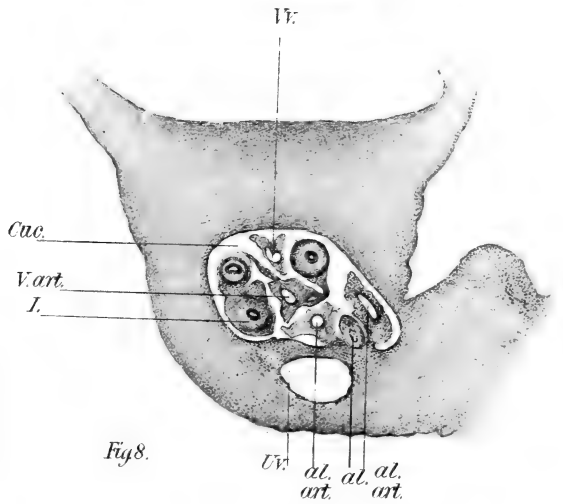

Fig 8.

Heliotype Co. Boston.

3 2044 107 350 613